

# Optimal Dental Therapy for Obstructive Sleep Apnea



Steven R. Olmos, DDS

## INTRODUCTION

*Optimal* is very different than *acceptable*, especially if you are the patient. This case study will highlight the need for a structural assessment of the 4 points of the airway prior to treatment utilizing CBCT (i-CAT). In addition, this case report will demonstrate how successful resolution of severe apnea with an oral appliance on a patient for whom continuous positive airway pressure (CPAP) had little effect on excessive fatigue until the nasal airway was addressed.

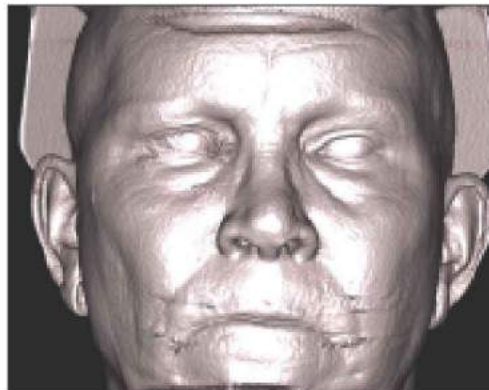


Chase Bennett, DDS

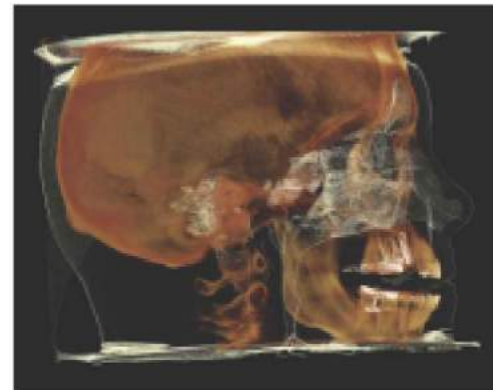## Background

Since 2004, the American Academy of Sleep Medicine has formally accepted the use of oral appliances to treat obstructive sleep apnea (OSA). Consequently, there has been a dramatic increase in dentists delivering this type of care. This is evidenced by the growth of academies that provide board certification in dental sleep medicine such as the American Board of Dental Sleep Medicine and the American Board of Craniofacial Dental Sleep Medicine. It is important that dentists treating OSA have a strong background in temporomandibular disorders (TMDs) as OSA symptoms precede the first-onset TMD as found in the NIH-funded "Orofacial Pain: Prospective Evaluation and Risk Assessment" study, also known as OPPERA.<sup>1</sup>

This is great news for patients as more dentists are screening for OSA, and most people who have OSA have not been diagnosed (more than 80%). Extrapolated data from the Wisconsin Sleep Cohort Study estimated that the overall prevalence of OSA was 9% for women and 24% for men.<sup>2</sup> The adult prevalence of OSA in general dentistry practices is 33% for men and 7% for women.<sup>3</sup> So 40% of your adult patients have a diagnosable OSA problem, and that does not include the patients who have lesser forms such as upper airway resistance syndrome (UARS), snoring, or are children (who have an equal or greater presentation of sleep breathing disorders). The fact that OSA and periodontitis are significantly linked is vital to our treatment plans for these conditions.<sup>4-6</sup> The fact that nightguards make OSA worse makes it imperative to find the origin of nocturnal brux-



CBCT 3-D soft-tissue rendering of patient.



CBCT sagittal view of hard tissues and airway.

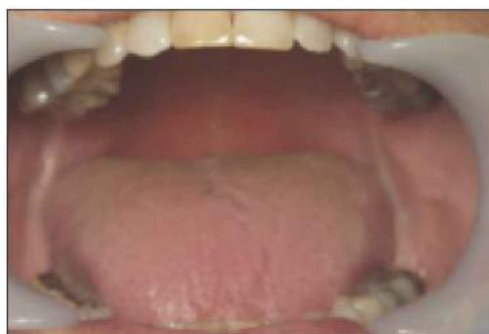

Figure 1. Tongue posture above the occlusal plane.

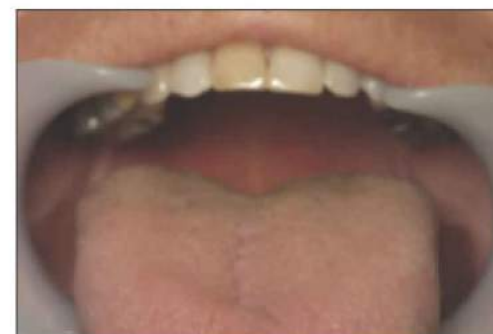

Figure 2. Mallampati 4, all indicating a minimal oral volume.

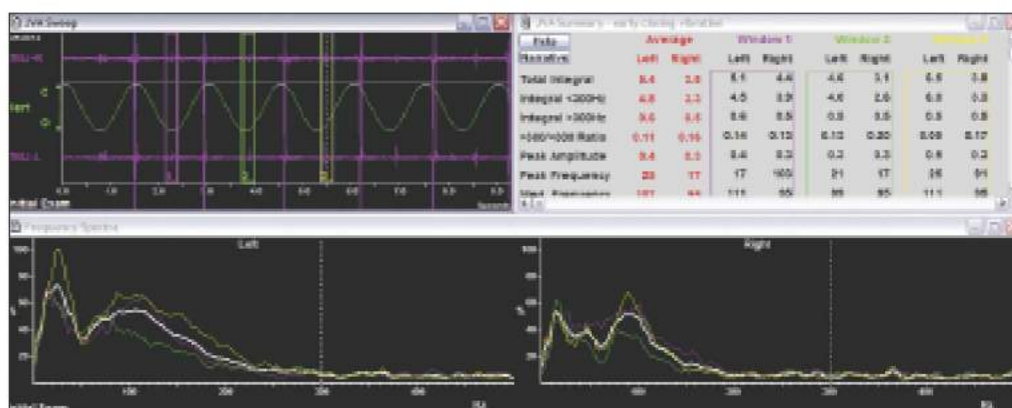


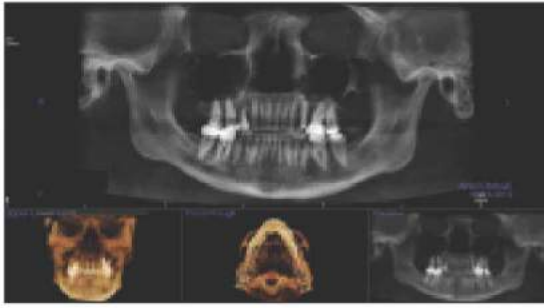
Figure 3. Disc movement without perforations and consistent with inflammation. The vertical dotted line separates soft-tissue vibrations (zero to 300 Hz) from hard-tissue vibrations (> 300 Hz).

ism.<sup>7-9</sup> The Frost & Sullivan firm reports that the US markets for oral appliances (OAs) for OSA, both custom and non-custom, will more than double by 2020.<sup>10</sup> The most dynamic sector, custom OAs, is expected to see a fivefold revenue increase in that period.

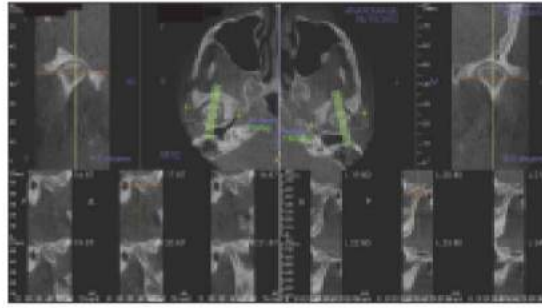
Lesser forms of airway obstruction such as UARS and mild and moderate OSAs demonstrate Epworth scores on average of

13 out of 24 in a study of military personnel.<sup>11</sup> The Epworth Sleepiness Scale (ESS) is an industry standard for evaluation of excessive daytime sleepiness and an indicator of the presence of a sleep breathing disorder. Normal controls have an ESS score of  $5.9 \pm 2.2$ , demonstrating baseline. Patients with primary snoring had ESS scores greater than  $6 \pm 3.0$ . Sleep disorders such as periodic leg movement disorder, OSA syn-

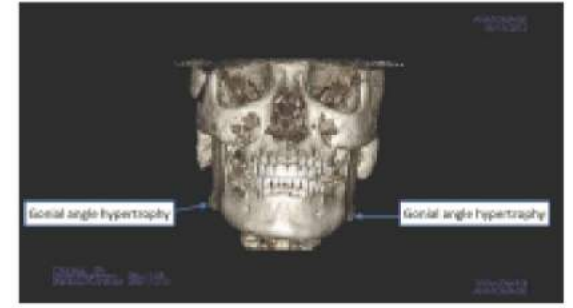




**Figure 4.** CBCT scan provided 3-D information on the condyles.



**Figure 5.** 3-D imaging of the joints reveals osteogenic remodeling of the condyles and fossa indicating long-term stress to these joints.



**Figure 6.** Scan showing patient's right and left gonial angle hypertrophy.

drome, narcolepsy, and idiopathic hypersomnia all had ESS values greater than 9.<sup>12</sup>

#### CASE REPORT

A 57-year-old white female was referred to our office (on August 15, 2012) by her family physician. She presented with a chief complaint of fatigue, significant daytime drowsiness, an unrefreshed feeling in the morning, frequent awakenings and an inability to tolerate CPAP. Her neck circumference was 14.5 inches, height 5' 8," weight 200 lb, BMI 39.06, B.P. 116/117, pulse 70, respirations 16, and temperature 97.7. Her medical history was lengthy: right hip replacement, right brain surgery to remove tissue and hippocampus, "oral surgery to correct over- and underbite," "several changes in mouth with appearance resulting in grinding rear teeth," and L-5 and S-1 disc repair. She had a medication regimen for the treatment of hypertension, epilepsy, gastroesophageal reflux (GERD), migraines, osteoarthritis, thyroid problems, anxiety, depression, and difficulty concentrating. Her ESS score was 14.

The patient's medications, upon presentation, were as follows: Simcor (statin drug for cholesterol) 500 mg/20 mg once daily, Nuvigil (stimulant for excessive daytime sleepiness) 250 mg once daily, Synthroid (hypothyroid function) 137 mcg once daily, Levetiracetam (Keppra) (anti-convulsion drug used to treat seizures)

1,500 mg twice daily, Trileptal (anti-convulsion drug used to treat seizures) 450 mg twice daily, Viibryd (SSRI antidepressant) 40 mg once daily, Losartan (anti-hypertensive, angiotensin II receptor antagonist) 50 mg once daily, Nexium (proton pump inhibitor that decreases the amount of acid produced in the stomach) (GERD) 40 mg daily, Intuniv (multivitamin) 4 mg daily, and aspirin 81 mg once daily.

Clinically, she had tongue posture above the occlusal plane, hyperkeratosis (B), retraction of the tongue into the airway, and Mallampati 4, all indicating a minimal oral volume (Figures 1 and 2). This meant that a minimally invasive

oral appliance should be used to treat the OSA. She had no headaches or facial pain complaints. Muscle palpation was negligible and she had normal ranges of mandibular movement. The maximum opening was 45 mm (Figures 1 and 2) with lateral movements of 12 and 10 mm left and right, respectively. Normal ranges of mandibular movement were 42 to 52 mm maximum opening and 10 to 14 mm lateral movements.<sup>13</sup> Dynamic evaluation of the jaw joints in function was performed using Joint Vibration Analysis (JVA [BioResearch]) and found to be within normal limits for soft tissue and without perforations to the discs bilaterally (Figure 3).



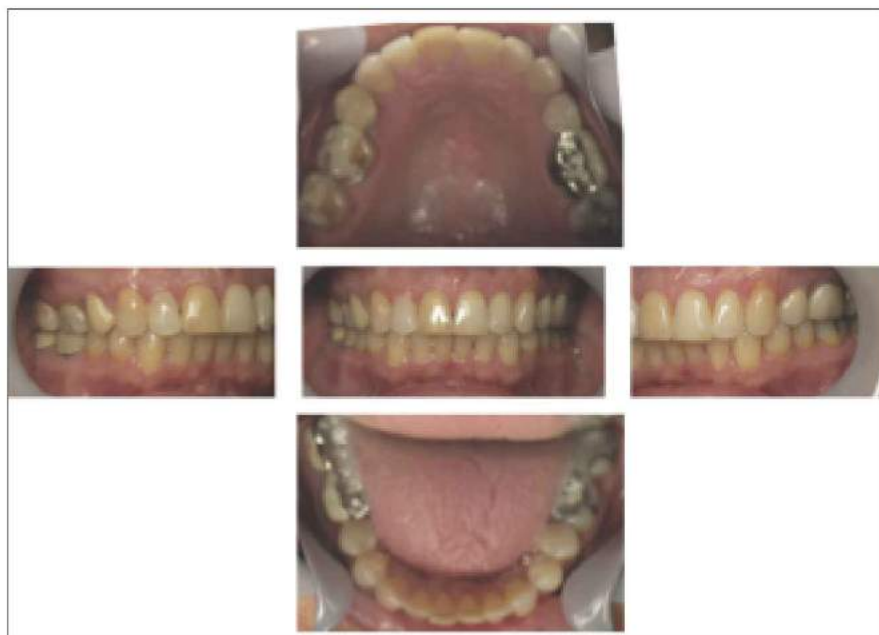

Figure 7. Occlusal analysis: Class II with attrition from bruxism.

The 3-D imaging of the joints revealed osteogenic remodeling of the condyles and fossa indicating long-term stress to these joints (Figures 4 and 5).

Hypertrophied gonial angles are the result of frequent and continued contractions of the superficial masseter muscles bilaterally, which are associated with increased hypercapnea (increases  $\text{CO}_2$  in the blood).<sup>14,15</sup> Hypercapnea is the stimulus to breathe in OSA. The patient's gonial angle hypertrophy was clearly seen on the scan (Figure 6).

Occlusal analysis was Class II with attrition from bruxism. Standard photographic records were also captured (Figure 7).

The patient was diagnosed by a board-certified sleep physician utilizing polysomnography (PSG) with severe OSA. Her apnea/hypopnea index (AHI) was 79.9 (an AHI > 30 is considered severe). The results of her PSG were as follows: arousal index: 21.9 (10.3 from AHI/respiratory disturbance index [RDI], 8.5 spontaneous, 3.1 snore). The patient slept supine all night: N1 sleep: 12.3% of total sleep time (TST); N2 sleep: 87.7% of TST; N3 sleep: zero; and REM sleep: zero.

Our patient received no stage 3 or REM sleep. This meant that she had limited ability to produce growth hormone and had terrible memory problems. Growth hormone is produced in stage 3 delta wave deep sleep and is essential for healing. Cognitive memory is an important function of REM sleep and without it, memory would be significantly affected.

Lowest  $\text{O}_2$  was 77%. She spent 37 minutes or 27% of TST below 90% blood oxygen, and her CPAP titration was 8 cm  $\text{H}_2\text{O}$  to reduce events to zero.

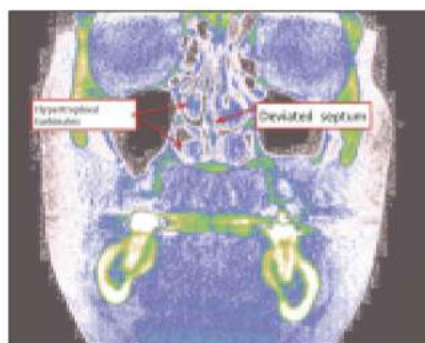


Figure 9. The 3-D scan showing turbinates and septum issues.

She tried CPAP nasal cannula for 8 months; however, pressure, leaks, and the noise kept her awake. So, even though the CPAP was effective, it was impossible for her to wear. This points out the most common flaw in the evaluation and treatment of OSA. Patients are evaluated for their sleep breathing pathology via a sleep study; however, rarely are patients evaluated for the origin of the obstructions. As a result, very often they have nasal obstructions and are given a CPAP without a physical or imaging of the airway, which leads to problems with mask leakage.

The first step to an effective treatment plan for OSA must include a full-head CBCT scan to determine the 4 points of obstruction. (For a detailed explanation of the 4 points of obstruction [Figure 8] and how to evaluate using CBCT (i-CAT), see the March/April 2015 edition of *Orthodontic Practice US*.<sup>16</sup>) Examination of the patient's 4 points of obstruction—nasal valve, naso-pharyngeal, velopharynx and oropharynx—demonstrated that, in addition to her positional apnea (base of tongue and velopharynx), she had nasal obstruction (see CBCT image in Figure 9).

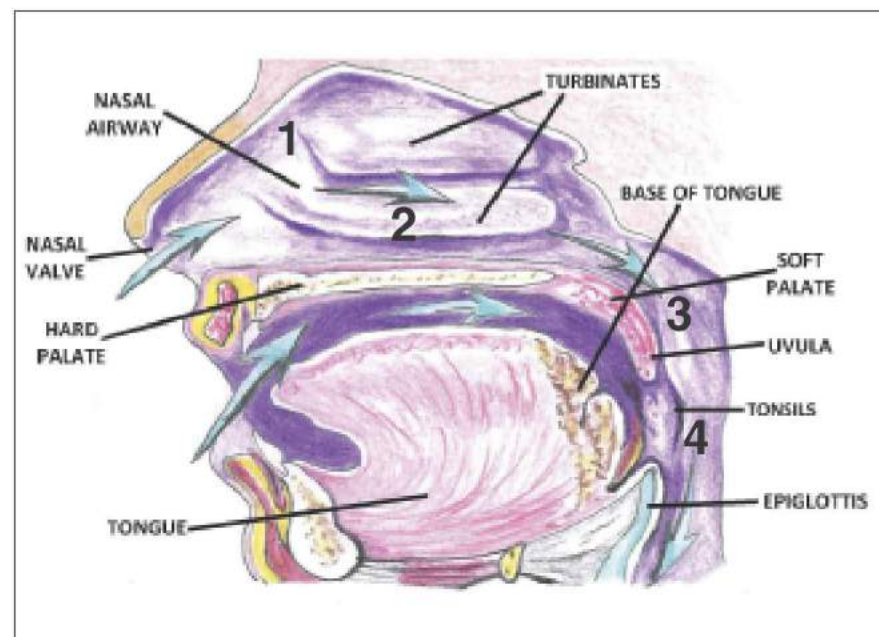


Figure 8. Diagram of the 4 points of obstruction. (Illustration by Brett Steed.)

Nasal airway resistance and BMI are the most limiting factors in treating OSA patients with oral appliance therapy (OAT).<sup>17</sup> Nasal airway obstruction is directly linked to daytime fatigue.<sup>18</sup>

The i-CAT imaging software allows for volumetric evaluation of the oropharyngeal airway. This patient had a severely compromised airway with a minimum of 61.3  $\text{mm}^2$ . The color scale demonstrates that the bottom end of evaluation is 100  $\text{mm}^2$  (Figures 9 to 11). Our treatment plan included OAT (EMA II), ENT consult, and a follow-up sleep study. The FDA-approved orthotic was delivered on September 5, 2012 (Figure 12).

The Sibilant Phoneme bite registration was utilized as the starting position for appliance fabrication because it is physiologic as opposed to a construction technique. It is the only bite registration technique that has been proven and published in a peer-reviewed journal to open the airway, but most importantly, reduce collapse.<sup>19</sup> Patients with OSA don't stop breathing during wakefulness; they only stop breathing when they are asleep. So the volume of the oropharyngeal airway is less important than the collapse. This means that titration is rarely necessary using the phonetic bite registration as a starting point. This particular patient is a perfect example of this, as her appliance never needed to be titrated. The oropharyngeal volumes (Figure 13) at baseline and with the bite registration show little improvement in wakeful breathing; however, these small changes resulted in resolution of her severe apnea.

Within 2 weeks of delivery of the oral appliance, her fatigue and daytime drowsiness were reduced by 30%. Her

symptom of feeling unrefreshed upon awakening had reduced 50%.

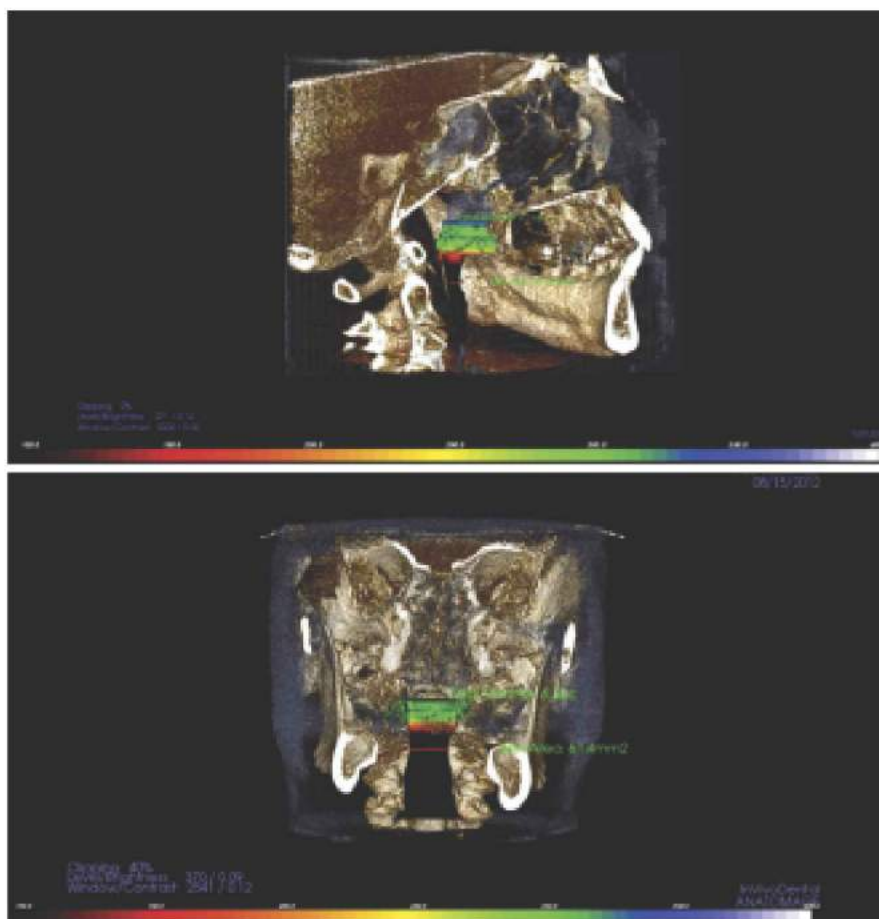
A follow-up home sleep test was performed on October 20, 2012 (Braebon MediByte), and had these results: AHI: 6.2, RDI: 9.8,  $\text{O}_2$  below 90%: 0.5 minutes or 0.1%, min  $\text{O}_2$ : 87%, and supine sleep: 100%. An AHI of 5 or less is considered normal. Success utilizing OAT on patients with severe apnea is defined as reducing the AHI by 50%, ESS scores less than 8, and blood oxygenation greater than 90%.<sup>20</sup> Her ESS score was 10 at this point, demonstrating that daytime fatigue was a significant problem.

She was reluctant to see the ENT specialist to whom she was referred for her nasal obstruction. She finally relented after we had demonstrated effective relief of fatigue utilizing Provent nasal valves (no longer on market; replaced by Theravent). She had nasal surgery on December 20, 2012, and after the 6-week healing process, her fatigue was resolved, multiple awakenings were 90% improved, and her daytime drowsiness was resolved.

She was seen for re-evaluation (on April 13, 2015) with the following results: Simcor, Nuvigil, Keppra, and Nexium had all been discontinued in 2014. That meant she no longer needed medication for elevated cholesterol, excessive daytime sleepiness, seizure activity, or GERD. Her new ESS score was a 5. Soft-tissue hypertrophy from diet and allergies can block the nasal airway, so we recommended a xylitol nasal spray (Xlear). Xylitol is a sugar that is antimicrobial and anti-inflammatory. It is used for patients with dry mouth who are at risk for caries and periodontal disease.

A comparison of i-CAT images of





Figures 10 and 11. Airway calculations in various views.

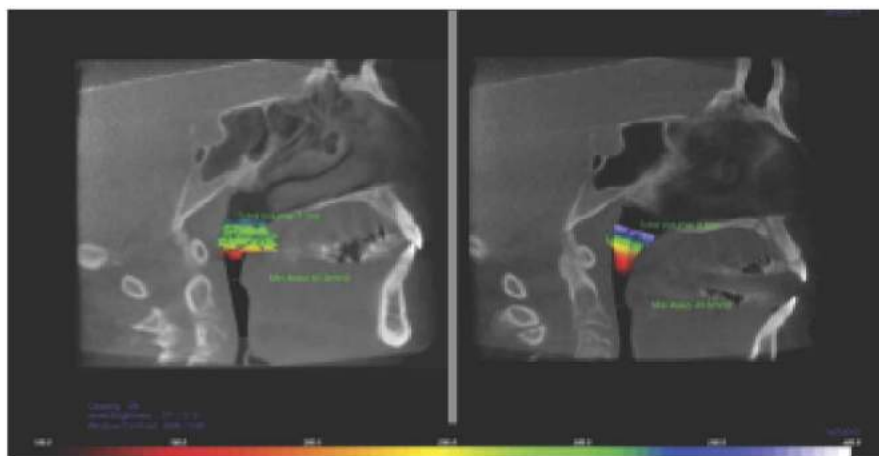


Figure 13. Baseline airway dimensions (left) and with bite registration (right).

the nasal passages demonstrates little soft-tissue hypertrophy and a straighter septum that resulted in a dramatic increase in nasal airflow (Figure 14). A very interesting finding was that the oropharyngeal airway was greater after the nasal surgery. The minimum increased from 61.3 mm<sup>2</sup> to 213 mm<sup>2</sup> (Figure 15).

#### CLOSING COMMENTS

This case report serves to highlight that too much emphasis is placed on developing big airways, without the understanding that prevention of collapse of the airway is most important as well as nasal airflow.<sup>21</sup> As demonstrated in this case, a combined or hybrid therapy of OAT and nasal surgery, directed by a dentist, was the

optimal treatment. The dentist is clearly in position to be the central triage professional for treatment options with the CBCT as the vital tool in this process. Without a CBCT scan, patients can suffer from multiple ineffective treatment plans. ♦

#### References

- Sanders AE, Essick GK, Fillingim R, et al. Sleep apnea symptoms and risk of temporomandibular disorder: OPPERA cohort. *J Dent Res*. 2013;92(suppl 7):70S-77S.
- Young T. Rationale, design, and findings from the Wisconsin Sleep Cohort Study: toward understanding the societal burden of sleep-disordered breathing. In: Bixler EO, ed. *Sleep Medicine Clinics: Epidemiology of Sleep Disorders: Clinical Implications*. Philadelphia, PA: Saunders; 2009:37-46.
- Levendowski DJ, Morgan T, Montague J, et al. Prevalence of probable obstructive sleep apnea risk and severity in a population of dental patients. *Sleep Breath*. 2008;12:303-309.
- Ahmad NE, Sanders AE, Sheats R, et al. Obstructive sleep apnea in association with

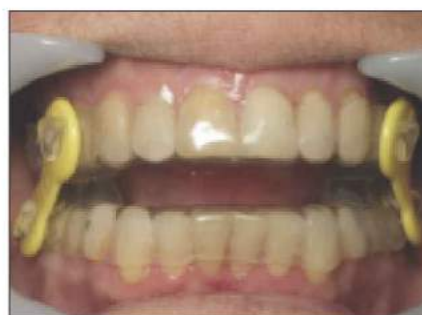

Figure 12. Patient with seated appliance.

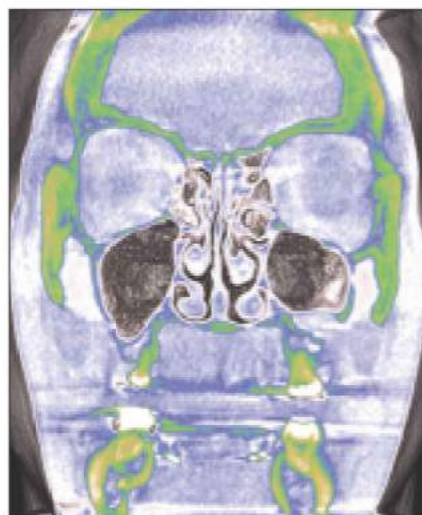


Figure 14. Substantial increase in airflow.

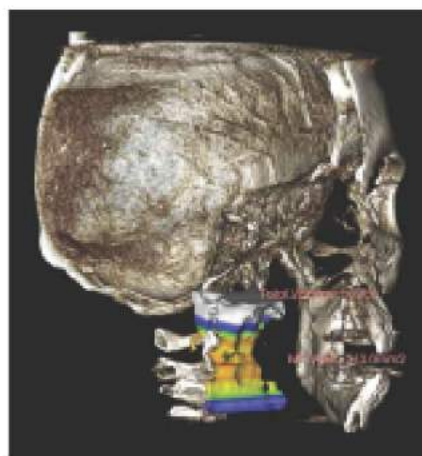


Figure 15. Increase in size of airway after nasal therapy.

- periodontitis: a case-control study. *J Dent Hyg*. 2013;87:188-199.
- Nizam N, Basoglu OK, Tasbakan MS, et al. Salivary cytokines and the association between obstructive sleep apnea syndrome and periodontal disease. *J Periodontol*. 2014;85:e251-e258.
- Gunaratnam K, Taylor B, Curtis B, et al. Obstructive sleep apnea and periodontitis: a novel association? *Sleep Breath*. 2009;13:233-239.
- Nikolopoulou M, Ahlberg J, Visscher CM, et al. Effects of occlusal stabilization splints on obstructive sleep apnea: a randomized controlled trial. *J Orofac Pain*. 2013;27:199-205.
- Gagnon Y, Mayer P, Morisson F, et al. Aggravation of respiratory disturbances by the use of an occlusal splint in apneic patients: a pilot study. *Int J Prosthodont*. 2004;17:447-453.
- Nikolopoulou M, Naeije M, Aarab G, et al. The effect of raising the bite without mandibular protrusion on obstructive sleep apnoea. *J Oral Rehabil*. 2011;38:643-647.
- Industry New: US Oral Appliance Market to Double by 2020. *Sleep Review*. Published on March 18, 2015. [sleepreviewmag.com/article/us-oral-appliance-market-double-2020](http://sleepreviewmag.com/article/us-oral-appliance-market-double-2020). Accessed on June 22, 2015.
- Powers CR, Frey WC. Maintenance of wakefulness test in military personnel with upper airway resistance syndrome and mild to moderate

obstructive sleep apnea. *Sleep Breath*. 2009;13:253-258.

- Johns MW. A new method for measuring daytime sleepiness: the Epworth sleepiness scale. *Sleep*. 1991;14:540-545.
- Grummons D. Temporomandibular disorders: the problem and orthodontic perspectives. In: Grummons D. *Orthodontics for the TMJ/TMD Patient*. Scottsdale, AZ: Wright and Co. Publishers; 1994:19-20, chapter 1.
- Hollowell DE, Suratt PM. Activation of masseter muscles with inspiratory resistance loading. *J Appl Physiol* (1985). 1989;67:270-275.
- Hollowell DE, Suratt PM. Mandible position and activation of submental and masseter muscles during sleep. *J Appl Physiol* (1985). 1991;71:2267-2273.
- Olmos S. CBCT in the evaluation of airway—minimizing orthodontic relapse. *Orthodontic Practice US*. 2015;6:34-37.
- Zeng B, Ng AT, Qian J, et al. Influence of nasal resistance on oral appliance treatment outcome in obstructive sleep apnea. *Sleep*. 2008;31:543-547.
- Hussain SF, Cloonan YK, Rahbar MH, et al. Association of self-reported nasal blockage with sleep-disordered breathing and excessive daytime sleepiness in Pakistani employed adults. *Sleep Breath*. 2010;14:345-351.
- Singh GD, Olmos S. Use of a sibilant phoneme registration protocol to prevent upper airway collapse in patients with TMD. *Sleep Breath*. 2007;11:209-216.
- Ferguson KA, Cartwright R, Rogers R, et al. Oral appliances for snoring and obstructive sleep apnea: a review. *Sleep*. 2006;29:244-262.
- Ng AT, Gotsopoulos H, Qian J, et al. Effect of oral appliance therapy on upper airway collapsibility in obstructive sleep apnea. *Am J Respir Crit Care Med*. 2003;168:238-241.

**Dr. Olmos** is an internationally recognized lecturer and researcher, and the founder of the TMJ & Sleep Therapy Centres International. He graduated from the University of Southern California School of Dentistry, and has dedicated the past 26 years to the fields of craniofacial pain, TMD, and sleep-related breathing disorders. He has extensive post-graduate education and board certifications in both craniofacial pain and dental sleep medicine, and he is an adjunct professor at the University of Tennessee College of Dentistry. Dr. Olmos is currently directing research in these fields through data collection at 32 TMJ & Sleep Therapy Centres spanning 6 countries. This effort is focused to establish protocols and bridge the gap between dentistry and medicine for optimal treatment outcomes. He can be reached at (877) 865-4325 or via the website [tmjtherapycentre.com](http://tmjtherapycentre.com).

*Disclosure: Dr. Olmos discloses that he has been sponsored for courses by Imaging Sciences, BioResearch, and Braebon.*

**Dr. Bennett** is a second-generation dentist from Tulsa, Okla, where he attended Oklahoma State University. Dr. Bennett graduated from the College of Dentistry with very special distinction while completing an externship at the renowned Tufts University Dental School's Craniofacial Pain and Dental Sleep Center under the direction of Dr. Noshir Mehta in Boston. In 2014, Dr. Bennett became the youngest dentist ever to achieve Diplomate status in the American Board of Craniofacial Pain and the disciplines of Craniofacial Pain and Sleep Disordered Breathing. Currently Dr. Bennett is the Director of the TMJ and Sleep Therapy Centre of San Diego and the Craniofacial Pain Center of Colorado. Dr. Bennett lectures locally and nationally in the fields of Craniofacial Pain and Dental Sleep Medicine and is involved in multiple research projects. He can be reached at (619) 466-2774 or via email at [drbennett@tmjtherapycentre.com](mailto:drbennett@tmjtherapycentre.com), or online at [tmjtherapycentre.com/sandiego](http://tmjtherapycentre.com/sandiego).

*Disclosure: Dr. Bennett reports no disclosures.*